

UZ Universitair Ziekenhuis Gent



SIRspheres: a case report

Karen Geboes
 BGDO meeting
 14 Januari 2017

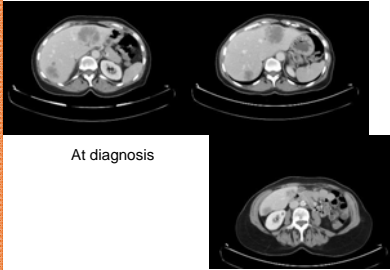
© 2014 Universitair Ziekenhuis Gent

UZ blood, ademhaling & spijsvertering
 Universitair Ziekenhuis Gent

- 2010, woman *1949
- appendectomy at the age of 5
- hypercholesterolemia
- 07/06/2007: melanoma of the left leg:
 Breslow 0.6 mm, Clark III, no ulcer (pT1a)
- 8/2010: sigmoid cancer with liver metastases, CEA 273
- mutation in KRAS

© 2014 Universitair Ziekenhuis Gent

UZ blood, ademhaling & spijsvertering
 Universitair Ziekenhuis Gent




At diagnosis

© 2014 Universitair Ziekenhuis Gent

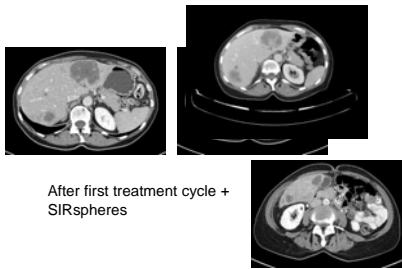
UZ blood, ademhaling & spijsvertering
 Universitair Ziekenhuis Gent

- 9/2010: Colonic stent because of obstruction
- Start FOLFOX + radio Yttrium ⁹⁰ spheres



© 2014 Universitair Ziekenhuis Gent

UZ blood, ademhaling & spijsvertering
 Universitair Ziekenhuis Gent

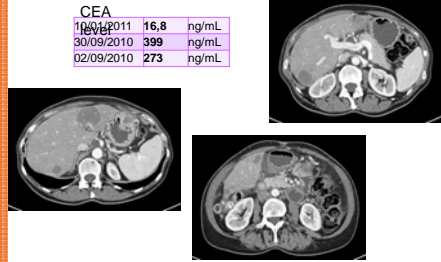


After first treatment cycle + SIRspheres

© 2014 Universitair Ziekenhuis Gent

UZ blood, ademhaling & spijsvertering
 Universitair Ziekenhuis Gent

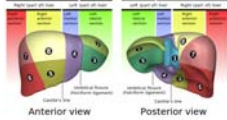
CEA level	ng/mL
16/03/2011	16,8
30/09/2010	399
02/09/2010	273



© 2014 Universitair Ziekenhuis Gent

UZ Universitair Ziekenhuis Gent

- 11/04/2011: Bisegmentectomy (2-3), resection segment 7 + RFA in segment 5 and 6
 After 13 treatments – 11 with oxaliplatin: PNP & thrombopenia
 Surgical report: blue liver, hard – other structures: fragile

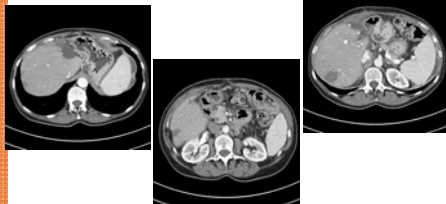


- 05/2011: Obstruction: stent-in-stent
- 03/06/2011: Resection of primary: ypT3N0 (0/20)

© 2014 Universitair Ziekenhuis Gent

UZ Universitair Ziekenhuis Gent

FOLLOW-UP



© 2014 Universitair Ziekenhuis Gent

UZ Universitair Ziekenhuis Gent

CEA	ng/mL
06/03/2012	1,91
03/04/2012	1,33
03/01/2012	1,63
14/11/2011	1,71
26/09/2011	1,67
25/07/2011	1,34
06/07/2011	1,28
10/01/2011	16,8
30/09/2010	399
02/09/2010	273

← Last SURG

☺ GOOD

© 2014 Universitair Ziekenhuis Gent

UZ Universitair Ziekenhuis Gent

☹ BAD

- 3/2011: duodenal ulcer
- 11/2011: inflammation and edema in duodenum esophageal varices

Doppler ultrasound:
 Partial occlusion portal vein?
 Normal flow

- 4/2012: duodenal scar, esophageal varices

	AST	ALT	bilirubin
05/06/2012	50	51	0,5
03/04/2012	66	67	0,6
14/11/2011	59	53	0,6
06/07/2011	46	36	0,4
23/04/2011	64	48	0,5
12/04/2011	621	276	0,9
11/04/2011	380	161	1,4
10/04/2011	72	46	0,5
01/04/2011	74	50	0,6
29/12/2010	81	53	0,8
04/10/2010	44	46	0,3
02/10/2010	59	57	1,0
01/10/2010	73	49	0,9
27/09/2010	36	25	0,3
02/09/2010	24	16	0,3

© 2014 Universitair Ziekenhuis Gent

UZ Universitair Ziekenhuis Gent

Pathology report liver resection:

Segment 2-3: one lesion consisting primarily of necrosis and fibrosis, but also containing adenocarcinoma, yttrium beads in the lesion and in the surrounding liver parenchyma.

Segment 7: presence of a lesion consisting of necrosis. Scattered yttriumbeads. No arguments for carcinoma.

Biopsy segment 6: predominantly necrosis and fibrosis. Localisation of adenocarcinoma. Yttrium beads.

In the surrounding liver parenchyma increased periportal and perisinusoidal fibrosis. There are no arguments for cirrhosis.

Gallbladder: some infiltration by lymphocytes and plasmocytes; yttrium beads in the subserosa

© 2014 Universitair Ziekenhuis Gent

UZ Universitair Ziekenhuis Gent



© 2014 Universitair Ziekenhuis Gent

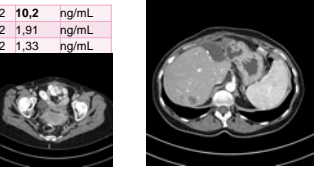
UZ Universitair Ziekenhuis Gent

Control doppler ultrasound: normal flow, no thrombosis

- 08/2012: dilatation of colonic anastomosis

CEA level

20/01/2012	10,2	ng/mL
05/06/2012	1,91	ng/mL
03/04/2012	1,33	ng/mL



© 2014 Universitair Ziekenhuis Gent

UZ Universitair Ziekenhuis Gent

- 10/2012: start FOLFIRI-avastin

	AST	ALT	bilirubin
16/02/2013	19	25	0,8
15/02/2013	22	27	
14/02/2013	26	37	
27/12/2012	53	46	0,7
23/08/2012	59	43	0,7

After 8 courses with some delay < thrombopenia mostly

- 2/2013: neutropenic fever, small bowel obstruction

XX UGLY

© 2014 Universitair Ziekenhuis Gent

UZ Universitair Ziekenhuis Gent

- Surgery on 22/2, 27/2, 2/3:
Adhesiolysis, (iatrogenic) perforations, tears in serosa, partial small bowel resection; ileostoma – redo surgeries because sutures don't hold – second stoma on small bowel
- Pathology report:
Denudation of the superficial layers of the small bowel, infiltration with mononuclear cells in the submucosa and muscle layer.
Obliterated vessels in the subserosa, recanalisation, old thrombi – scars.
Fibrinopurulent exudate on serosa, mixed infiltrate, granulation tissue, prominent vessels, congestion.
- Long hospitalisation – parenteral nutrition

© 2014 Universitair Ziekenhuis Gent

UZ Universitair Ziekenhuis Gent

CEA

20/01/2013	92,7	µg/L
27/12/2012	10,4	µg/L
23/08/2012	10,2	ng/mL

	AST	ALT	bilirubin
22/07/2013	85	56	1,5
16/02/2013	19	25	0,8
15/02/2013	22	27	

- 07/2013: External RT for liver metastasis segment 7

© 2014 Universitair Ziekenhuis Gent

UZ Universitair Ziekenhuis Gent

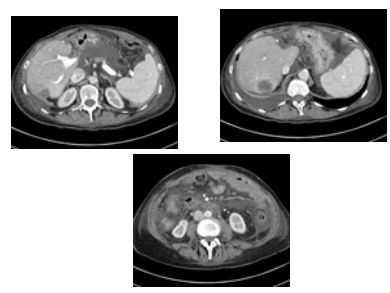
CEA

07/01/2014	98,3	µg/L	19/02/2014	53	41	5,2
09/10/2013	11,6	µg/L	09/10/2013	82	60	2,4
22/07/2013	92,7	µg/L	22/07/2013	85	56	1,5

- 07/01/2014: disease progression at the site of the local recurrence, liver and lung: start capecitabine
- 02/2014: Diarrhoea, bowel edema on CT scan: stop treatment

© 2014 Universitair Ziekenhuis Gent

UZ Universitair Ziekenhuis Gent



© 2014 Universitair Ziekenhuis Gent

UZ blood, ademhaling & spijsvertering
Universitair Ziekenhuis Gent

CEA level


15/01/2014	176	µg/L
28/02/2014	42,9	µg/L
07/01/2014	98,3	µg/L


	AST	ALT	bilirubin
13/05/2014	256	195	12,2
15/04/2014	185	131	8,7
17/03/2014	152	90	6,0
10/03/2014	113	74	4,9
01/03/2014	82	41	5,7
19/02/2014	53	41	5,2


© 2014 Universitair Ziekenhuis Gent 19

UZ blood, ademhaling & spijsvertering
Universitair Ziekenhuis Gent

Summary


GOOD


BAD


UGLY

- **Very good and long-lasting response with multimodality treatment:**
8/2010: diagnosis – 6/2011: last surgery – 8/2012: relapse
- **Comorbidities/complications related to treatment modalities**
e.g. liver 'toxicity' < surgery, local treatments, chemotherapy

© 2014 Universitair Ziekenhuis Gent 20