

BGDO Annual Meeting 2017:  
How to use Immunotherapy & Locoregional Treatments?

Hôpital Erasme ULB

## Use of CHIA and hepatic surgery Clinical case

Valerio Lucidi (Surgeon)  
Gontran Verset (Oncologist)

Department of Hepato-Biliary Surgery & Liver Transplantation  
Hôpital Erasme – ULB University  
Brussels – Belgium  
CCHB: Centre de Chirurgie Hépato-Biliaire - ULB



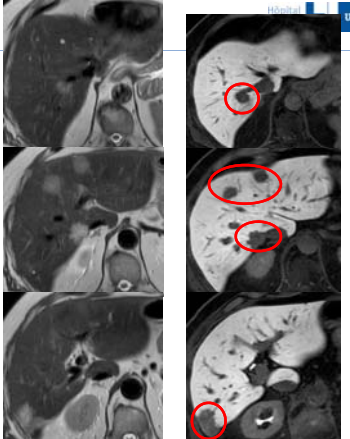

Hôpital Erasme ULB

### Case 1: initial colon cancer diagnosis

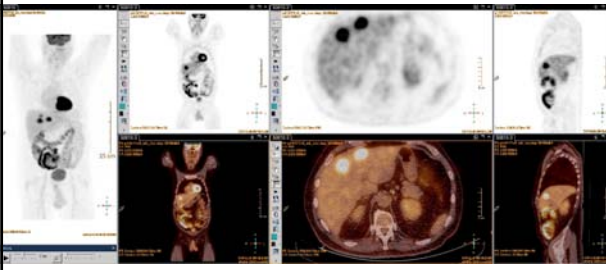
- 67 year old man
  - 78Kg 170cm BMI=27
- March 2014: Colonoscopy de « dépistage »
  - 4cm polipoid lesion at 23cm from am
  - Well differentiated adenocarcinoma
- April 2014
  - Left colectomy
    - pT1N0(0/15)M0
    - Kras=WT
    - BRAF=WT
  - No adjuvant chemotherapy

6 month follow-up

	11/2014
S3	19
S4a	22
S4	7
S6	38
S7	25
S8	23
S8	4
	mm
CEA	2,9



6 month follow-up



No extra-hepatic metastases

Hôpital Erasme ULB

### What attitude ?

- Liver Surgery ?
  - What kind?
- Chemo ?
  - Systemic
  - IA



Hôpital Erasme ULB

### Chemotherapy

- Systemic chemotherapy:
  - FOLFOX + Cetuximab x 5

**After 5 cycles of Chemotherapy**

	11/2014	3/2015
S3	19	10
S4a	22	13
S4	7	0
S6	38	36
S7	25	23
S8	23	10
S8	4	0
CEA	2,9	0,8

**What now?**

**Pre-operative work-up**

- Total Liver Volume = 1580 cc
- Left Liver (S1→S4) = 610 cc
- LL/TLV = 39%
- LL/BW = 0,78%
- Mebrofenin Liver Scintigraphy
  - Liver clearance = 14,89%/min
- PT=106% INR=0,95 Bili=0,34mg/dl Alb=40g/L
- PLT=143000 SGOT= 32 SGPT=26
- APRI score = 0,5 (predicting score of SOS)

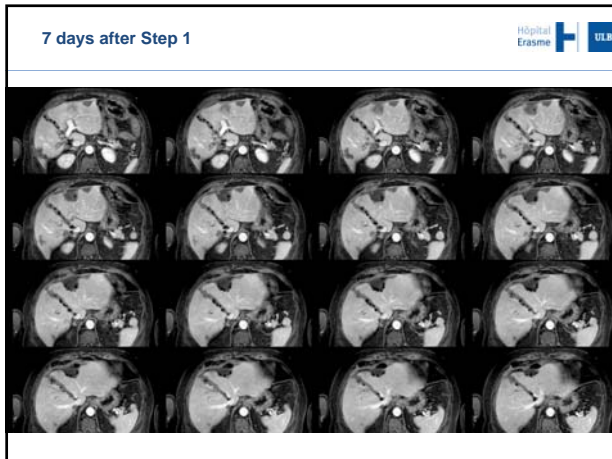
**What attitude?**

- Scheduled Surgery:
  - Right hepatectomy + 2 wedge resections in left liver

**What attitude?**

- Scheduled Surgery:
  - Right hepatectomy + 2 wedge resections in left liver

**ALPPS: Associating Liver Partition & Portal Embolisation for Stages Hepatectomy**



Day 7 after Step 1

- Total Liver Volume = 1580 cc → 1497cc
- Left Liver (S1→S4) = 610 cc → 730cc
- LL/TLV = 39% → 48 %
- LL/BW = 0,78% → 0,93%
- Mebrofenin scintigraphy
  - Liver cl = 14,89%/min → 10,53%/min
  - Liver cl for left liver = 5 %/min
- PT=88% INR=1,07 Bili=0,5mg/dl Alb=27g/L
- PLT=318000 SGOT= 48 SGPT=108

Step 2: right hepatectomy

- Step 1 + 2: No blood transfusion
- Uneventfull post-operative course
  - Little ascitis needing no treatment
- Total lenght of hospital stay: 14 days
- Post Step 2 LOS: 5 days

HISTOLOGY

	Initial MRI	Final MRI	mm	TRG Rubbia Brandt
S3	19	10	5	1
S4a	22	13	10	2
S4	7	0	?	?
S6	38	36	45	1
S7	25	23	30	Sclerosed angioma
S8	23	10	12	4
S8	4	0	?	?

What attitude after surgery?

- Simple Follow-up ?
- Systemic Chemo ?
- CIAH ?

What attitude after surgery?

CIAH x 6

- IA: Oxaliplatin 100 mg/m<sup>2</sup>
- Systemic: LV5-FU2

